



Review Article

Uses and mechanisms of apnoeic oxygenation: a narrative review

C. Lyons¹ and M. Callaghan²

1 Specialist Trainee, Department of Anaesthesia, Mater Misericordiae University Hospital, Dublin, Ireland

2 Consultant, Department of Anaesthesia, Galway University Hospitals, Galway, Ireland

Summary

Apnoeic oxygenation refers to oxygenation in the absence of spontaneous respiration or mechanical ventilation. It has been described in humans for over half a century and has seen a resurgence in interest given its potential to delay oxygen desaturation during airway management, especially with the advent of high-flow nasal cannulae. This narrative review summarises our current understanding of the mechanisms of gas exchange during apnoeic oxygenation and its diverse range of clinical applications, including its use at induction of anaesthesia and for the facilitation of 'tubeless anaesthesia'. Additional discussion covers use in critical care, obese, obstetric and paediatric sub-populations. The article also highlights current research efforts aiming to enhance the evidence base for the use of this technique.

*Correspondence to: C. Lyons

Email: craigmacliathain@gmail.com

Accepted: 2 December 2018

Keywords: airway management; apnoea; apnoeic oxygenation; high-flow nasal oxygen; THRIVE

This article is accompanied by an editorial by Lumb and Thomas, *Anaesthesia* 2019; **74**: 420–423; and an article by Hermez et al., *Anaesthesia* 2019; **74**: 441–449.

Introduction

The earliest description of apnoeic oxygenation was probably by Hook in 1667, achieved by continuous inflation of punctured canine lungs [1]. At the turn of the last century, intra-tracheal insufflation of oxygen in animals was described, more akin to modern methods [2].

In 1946, Comroe and Dripps documented two cases of apnoeic oxygenation via a tracheal tube in man; both patients having suffered respiratory arrest secondary to intracranial pathologies which were ultimately fatal [3]. Enghoff et al. demonstrated a similar technique in anaesthetised patients in 1951, and emphasised the essential conditions for success as '*a high percentage of oxygen in the lungs and in the dead space, a free airway and an adequate circulation*' [4], which remain the cornerstones of the modern-day technique. Apnoeic oxygenation has been applied in diverse clinical scenarios, commonly in the form of an apnoea test for brain stem death and more

recently via nasal cannulae during airway management and 'tubeless anaesthesia'. This article summarises the underlying physiology and its clinical applications.

Methods

We conducted a literature search (PubMed and Scopus) in January 2018, repeated in April 2018, to identify relevant articles. Key search terms included: 'apnoeic oxygenation', 'THRIVE', 'high-flow nasal oxygen', 'apnoea test' and 'ventilatory mass flow'. No date limits were set. The abstracts of identified articles were assessed for relevance, along with screening of their references for further relevant publications. A full-text review of 374 articles was undertaken, of which 116 were included in the final review.

Physiology

In the apnoeic patient, extraction of oxygen from the alveolus into the blood causes alveolar pressure to become

subatmospheric, generating a pressure gradient which enables the movement of additional administered oxygen into the alveolus [5]. This is termed 'aventilatory mass flow' [6], formerly referred to as 'diffusion respiration' [7] or 'apnoeic diffusion of oxygenation' [8]. Apnoeic oxygenation is facilitated by 'denitrogenation' of the patient's lungs, by breathing O_2 for a suitable duration, before the onset of apnoea. Otherwise, the persistence of nitrogen in the lung, combined with accumulating carbon dioxide, diminishes the pressure gradient available for oxygen transfer to the alveolus and hastens the onset of hypoxaemia [9]. Re-nitrogenation is prevented by the delivery of a fraction of inspired oxygen of 1.0 during the apnoeic period [10].

In this theory, the subatmospheric alveolar pressure also promotes carbon dioxide transfer from the blood to the alveolus. The pressure gradient is not immediately obliterated as the degree of oxygen extraction from the alveolus exceeds the degree of carbon dioxide return to the alveolus, given the capacitance of the body to buffer and store carbon dioxide, for example, bicarbonate formation by carbonic anhydrase [11]. With time, alveolar accumulation of carbon dioxide diminishes the pressure gradient for oxygen transfer to the alveolus and limits the duration of success of aventilatory mass flow [10]. 'Hypoventilatory mass flow' has been proposed as an alternative term to 'aventilatory mass flow' because, whenever carbon dioxide is being cleared from the alveolus, this implies 'ventilation' and is therefore not a true aventilatory state [12]. Additionally, the term acknowledges that carbon dioxide removal from the alveolus leads to a decline in alveolar pressure that can facilitate mass flow of oxygen into the alveolus or accommodate the transfer of further carbon dioxide from the blood.

The theory above also accommodates a possible role for cardiogenic oscillations, which are airflow alterations caused by contractions of the heart and may assist with gas exchange during apnoea [13]. The change in heart volume during the cardiac cycle is believed to promote gas movement by altering intrathoracic pressure [6, 14]. Additional contributions to pulsatile gas flow may arise from direct compression and expansion of the lung parenchyma adjacent to the heart and from pulsatile flow in the pulmonary vasculature [15, 16]. Gas mixing secondary to cardiogenic oscillations is believed to occur predominantly in the conducting airways, but can also arise in the acini [16]. The magnitude of its contribution to overall gas exchange in the apnoeic state remains unknown; oscillations may be enhanced by the apnoea-associated respiratory acidosis, which stimulates a tachycardia. The proposed mechanisms of apnoeic oxygenation are illustrated in Fig. 1.

Carbon dioxide clearance

The elimination of carbon dioxide from the body is limited during apnoeic oxygenation, such that hypercarbia and acidaemia ensue over time. During normal spontaneous ventilation, partial pressure of carbon dioxide (PCO_2) is highest in mixed venous blood (P_vCO_2), then in the alveolus (P_ACO_2), then in arterial blood (P_aCO_2). During the initial period of apnoeic oxygenation, venous, alveolar and arterial partial pressures of carbon dioxide transiently reach equilibrium [17]. Thereafter, the arteriovenous carbon dioxide gradient described above becomes reversed, with arterial PCO_2 exceeding venous PCO_2 . The reversal is attributed to retention of carbon dioxide within the pulmonary circulation due to impaired gas exchange, and is compounded by the Haldane effect, wherein oxygenation

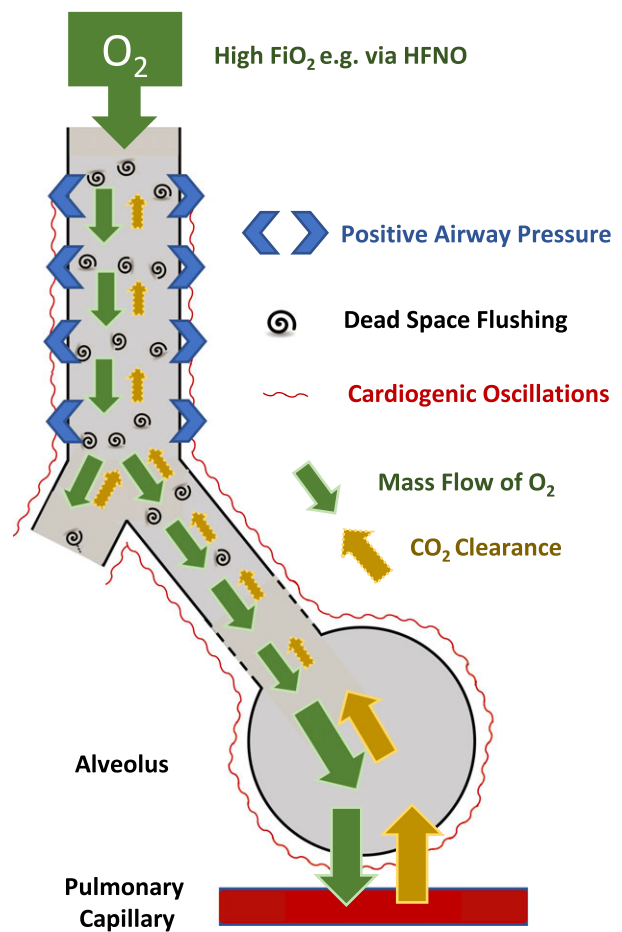


Figure 1 Apnoeic oxygenation involves the mass flow of a high fraction of inspired oxygen, aided by flushing of dead space, generation of positive airway pressure and cardiogenic oscillations. Higher flow rates can enable clearance of carbon dioxide.

of arterial blood displaces carbon dioxide from haemoglobin [18, 19].

The degree of carbon dioxide accumulation that occurs in the blood during the first minute of apnoea is greater than in any subsequent minute [19, 20]. Stock demonstrated a mean $P_a\text{CO}_2$ rise of 1.6 kPa during the first minute, followed by a rise of 0.45 kPa with each subsequent minute during complete airway obstruction in elective surgical patients, simulated by clamping the tracheal tube. Similar blood gas alterations have been observed during apnoea testing for brainstem death [19, 21, 22].

It is notable that some carbon dioxide clearance can occur, depending on the flow rate of administered gases and the proximity of their site of administration to the alveoli. Higher flow rates are believed to extend the region of turbulent gas flow more distally in the airways, resulting in improved gas exchange [23], sufficient to maintain a normocarbic state during apnoeic oxygenation in animals [24]. This degree of gas exchange has seldom been attained in human studies despite use of endobronchial catheter flow rates in excess of $0.5 \text{ l.kg.min}^{-1}$ [25, 26]. High-flow nasal oxygen attenuates the rise of carbon dioxide in the blood, with mean elevations of $0.21 \text{ kPa.min}^{-1}$ and $0.24 \text{ kPa.min}^{-1}$ in two case series [12, 27]. Preceding apnoeic oxygenation with a period of hyperventilation does not exert a prolonged effect on lowering $P_a\text{CO}_2$ [27].

The gradient between $P_a\text{CO}_2$ and end-tidal carbon dioxide (ET_{CO_2}) increases with apnoea duration (where the latter is measured at the first postapnoeic breath) [21]. Bohr hypothesised that this divergence was caused by atelectasis and ventilation–perfusion mismatch [28]. As a consequence, ET_{CO_2} measurements progressively underestimate the hypercarbic burden [12, 27].

High-flow nasal oxygen: novel mechanisms

Apnoeic oxygenation can be achieved with any device that enables administration of oxygen into the respiratory tract, including facemask, nasal cannula, nasopharyngeal catheter, supraglottic airway device, rigid bronchoscope, tracheal tube and front-of-neck catheter. Oxygen insufflation can also occur through channels located in direct and videolaryngoscopes [29, 30].

High-flow nasal oxygen represents a recent breakthrough in the area of apnoeic oxygenation, enhancing both oxygenation and carbon dioxide clearance as compared with low-flow nasal oxygen [12, 27, 31]. Proposed mechanisms include reduced dilution of administered oxygen by nitrogen [32], enhanced dead space flushing [33, 34], positive airway pressure generation

[35–41] and benefits derived from gas heating and humidification [42–44]. High-flow nasal oxygen promotes washout of gases from anatomical dead space, including more distal conducting airways, as demonstrated by scintigraphy studies in breath-holding subjects [33]. Sampling of inspired gases from tracheostomised patients has demonstrated a flow-dependent increase in inspired tracheal oxygen concentration and reduced rebreathing [33, 34].

Positive airway pressure generation by high-flow nasal oxygen increases end-expiratory lung impedance in spontaneously breathing patients [35, 36], which is consistent with an increase in end-expiratory lung volume and functional residual capacity [37]. It also assists with upper airway patency, as observed in patients with obstructive sleep apnoea, who have less inspiratory flow limitation with nasal insufflation [38]. A linear relationship exists between high-flow nasal oxygen flow rate and positive airway pressure generation in the nasopharynx of awake patients. Each 10-l increase in flow rate achieves an additional positive airway pressure of $0.5 \text{ cmH}_2\text{O}$ with an open mouth and $1 \text{ cmH}_2\text{O}$ with a closed mouth, albeit with significant inter-patient variability [36, 39, 40]. Furthermore, the heating and humidification of administered oxygen improves airway function through enhanced gas flow and pulmonary compliance [42], maintenance of ciliary function [43] and avoidance of the bronchoconstrictor response that arises with cold, dry gases [44].

A paper in this issue of the journal proposes a novel additional mechanism that may be responsible [45].

Apnoeic oxygenation during airway management

Levitan coined the acronym 'NODESAT' (nasal oxygen during efforts at securing a tube) to describe apnoeic oxygenation using unwarmed, dry oxygen via standard nasal cannulae at 15 l.min^{-1} to extend safe apnoea time [46]. Patel et al. later used the acronym 'THRIVE' (transnasal humidified rapid insufflation ventilatory exchange) to describe apnoeic oxygenation via heated and humidified high-flow nasal cannulae [31]. A perceived advantage of nasal cannulae for apnoeic oxygenation is that they do not obstruct access to the airway during tracheal intubation. A disadvantage is that they can impair the facemask seal if the clinician undertakes bag-mask ventilation. Another limitation is that apnoeic oxygenation has no proven role as a rescue technique for oxygenation in the already desaturating patient.

Airway management guidelines now support the use of apnoeic oxygenation during laryngoscopy [47–50]. A

recent review, compromised predominantly of low-flow insufflation techniques, concluded that apnoeic oxygenation prolonged time to oxygen desaturation without discernible adverse effects [51].

Two randomised controlled trials have compared the use of high-flow nasal oxygen and facemask oxygenation during rapid sequence induction (RSI) of anaesthesia. Mir et al. were unable demonstrate a difference in arterial PO_2 between the study groups; but given that time to intubation was twice as long in the high-flow nasal oxygen group, the authors implied that overall oxygenation had been improved [52]. Lodenius et al. demonstrated a greater incidence of desaturation $< 93\%$ in the facemask group during RSI when both groups had comparable apnoea duration [53]. Exclusion criteria included a body mass index $> 35 \text{ kg.m}^{-2}$, pregnancy and pre-operative requirement for non-invasive ventilation.

It is notable that published studies assessing the use of nasal oxygenation at induction of anaesthesia have combined its use as a pre-oxygenation and apnoeic oxygenation method, meaning that there is uncertainty whether advantage arises with high-flow nasal oxygen in both phases or in the apnoeic phase alone. It is possible that facemask pre-oxygenation (with an adequate seal for an adequate duration, with continuous positive airway pressure), is superior to nasal pre-oxygenation, as the latter can permit entrainment of room air by mouth. If so, nasal oxygen administration would be more suited as an isolated apnoeic technique. For example, the clinician can rest nasal

cannulae on the forehead while undertaking facemask pre-oxygenation, and place them nasally with onset of apnoea or immediately before laryngoscopy (Fig. 2). Other potential advantages associated with this approach are the ability to measure end-tidal oxygen concentration during facemask oxygenation, and the avoidance of either an ineffective seal or barotrauma from dual use of high-flow nasal oxygen and facemask oxygenation.

We now review evidence for use of apnoeic oxygenation techniques in some specific situations.

Urgent intubation, respiratory failure and critical illness

Apnoeic oxygenation reduces the incidence of clinically significant hypoxaemia during emergency intubation according to a recent systematic review [54]. A mixture of low- and high-flow techniques was included, and studies differed in their methods of pre-oxygenation, and included emergency department, intensive care unit (ICU) and pre-hospital settings. The pooled absolute risk of clinically significant hypoxaemia was 27.6% in the 'usual care' group and 19.1% in the 'apnoeic oxygenation' group, offering a relative risk reduction of 30%.

Clinically significant desaturation during intubation is most likely to arise in those patients with acute respiratory failure. The potential for benefit from apnoeic oxygenation in this population is uncertain. A recent trial compared pre-oxygenation and apnoeic oxygenation with facemask pre-oxygenation alone during intubation for acute respiratory

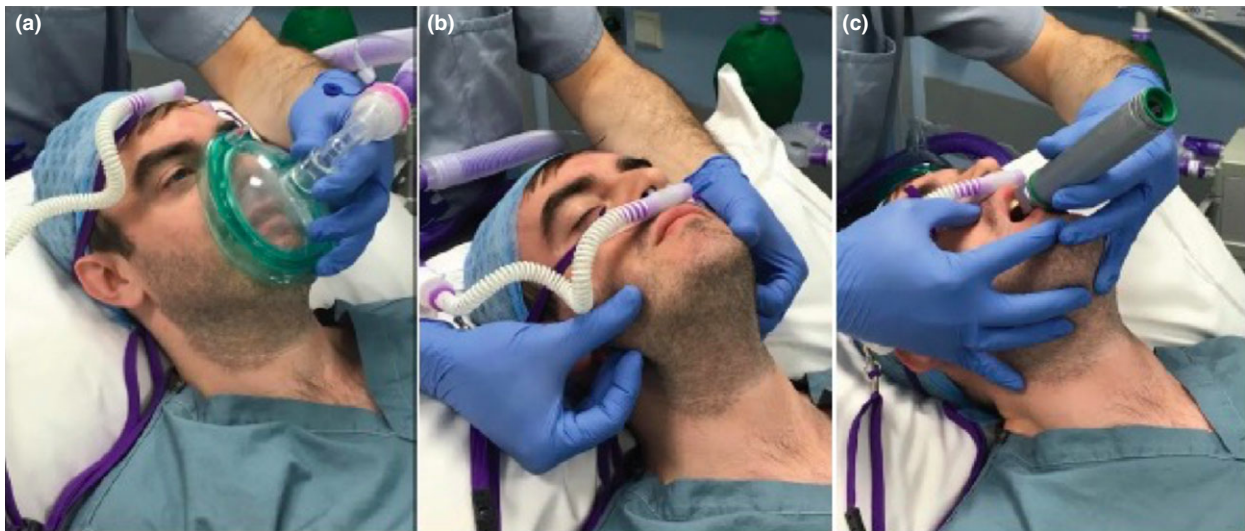

Figure 2 An approach to pre-oxygenation and apnoeic oxygenation at induction of anaesthesia. During facemask pre-oxygenation, nasal cannulae are placed on the forehead (a). After induction of anaesthesia, optional bag-mask ventilation is followed by lowering of the cannulae to the nares (b). This enables apnoeic oxygenation while awaiting onset of neuromuscular blockade and during laryngoscopy (c).

failure in the ICU, with a 25% incidence of desaturation to $S_pO_2 < 80\%$ in both groups [55]. Another recent trial demonstrated a reduced incidence of desaturation when non-invasive ventilation was incorporated into the pre-oxygenation process in similar patients [56]. The intervention arm received pre-oxygenation with non-invasive ventilation and high-flow nasal oxygen followed by apnoeic oxygenation with high-flow nasal oxygen, while the control arm comprised pre-oxygenation with non-invasive ventilation alone without apnoeic oxygenation. Desaturation to $S_pO_2 < 80\%$ was more common in the control arm. Clarity may arise from an ongoing multi-centre randomised controlled trial comparing high-flow nasal oxygen and non-invasive ventilation pre-oxygenation in patients with respiratory failure [57].

Beyond a reduced incidence of clinically significant hypoxaemia at intubation, clinical studies up to now have been under-powered to demonstrate a reduction in other adverse events, such as arrhythmia and cardiac arrest. Nonetheless, continuous nasal oxygenation (low flow or high flow), forms part of 'Plan A' in the first iteration of the Difficult Airway Society guidelines for tracheal intubation of critically ill adults [58, 59].

Obesity

Obese patients experience a more rapid onset of hypoxaemia during apnoea [60], which can be delayed by apnoeic oxygenation. Baraka et al. assessed the impact of pre-oxygenation alone compared with pre-oxygenation followed by oxygen insufflation via a nasopharyngeal catheter on the time to desaturation of morbidly obese patients at induction of anaesthesia [61]. The insufflation group demonstrated a longer time to desaturation over a 4-min study period. Ramachandran et al. measured the effects of apnoeic oxygenation via nasal cannulae at 5 l.min^{-1} on obese patients at induction of anaesthesia while simulating a Cormack and Lehane grade-4 view during laryngoscopy [62]. Those patients who received nasal oxygen were more likely to maintain $S_pO_2 \geq 95\%$ over a 6-min study period. Published studies utilising high-flow nasal oxygen have contained few obese patients and the magnitude of benefit this population can derive from this intervention remains uncertain.

Obstetrics

Guidelines issued in 2015 by the Difficult Airway Society and Obstetric Anaesthetists' Association for the management of difficult tracheal intubation in obstetric patients mention the potential role for apnoeic oxygenation via tight-fitting facemask, nasopharyngeal catheter or nasal

cannulae, based on evidence from non-obstetric settings [63]. The All India Difficult Airway Association recommends the universal use of 15 l.min^{-1} oxygen insufflation via nasal cannulae for obstetric general anaesthesia [64].

Pillai et al. undertook computational modelling of apnoeic oxygenation with high-flow nasal oxygen in 'virtual parturients' [65]: high-flow nasal oxygen increased the time to desaturation to 40% (an unusually low end-point) from 4.5 to 58 min. The clinical relevance of this modelling has been questioned and this magnitude of benefit has not yet been observed in clinical practice [66]. An ongoing trial (ACTRN12616000531415) aims to characterise the efficacy and safety of high-flow nasal oxygen as an isolated pre-oxygenation or apnoeic oxygenation technique in the obstetric population and is due for completion in 2019.

Paediatrics

Randomised controlled trials have shown a delayed time to oxygen desaturation with use of pharyngeal oxygen insufflation during elective tracheal intubation [29, 30]. In one study, apnoeic oxygenation with high-flow nasal oxygen at $1\text{--}2 \text{ l.kg.min}^{-1}$ reduced the incidence of desaturation during intubation when compared with a control arm that did not receive any supplemental oxygen during apnoea [67]. Another trial compared use of low-flow nasal oxygen at $0.2 \text{ l.kg.min}^{-1}$ ($F_{IO_2} 1.0$), high-flow nasal oxygen at 2 l.kg.min^{-1} ($F_{IO_2} 1.0$), and high-flow nasal oxygen 2 l.kg.min^{-1} ($F_{IO_2} 0.3$) at induction of anaesthesia [68]. Oxygen desaturation was the cause of study termination for all patients in this last group. However, for 35 of all 38 patients receiving an F_{IO_2} of 1.0, the study was terminated due to attainment of a transcutaneous PCO_2 of 8.7 kPa or an apnoea duration of 10 min, before oxygen desaturation occurred. Therefore, this study was unable to determine whether administration of 100% oxygen via high-flow nasal cannulae delays time to oxygen desaturation when compared with low-flow nasal cannulae [69].

Both aforementioned high-flow nasal oxygen studies did not demonstrate clearance of carbon dioxide when compared with control arms, questioning whether this is attainable in a paediatric population despite high-flow insufflation.

Tubeless anaesthesia

Short-duration laryngeal surgery in apnoeic patients with avoidance of tracheal intubation was first reported by Woodman in 1959, who concluded that the technique "*affords the operator a completely relaxed patient plus an unobstructed view of the larynx*" [70]. Recently, apnoeic oxygenation with high-flow nasal oxygen has enabled

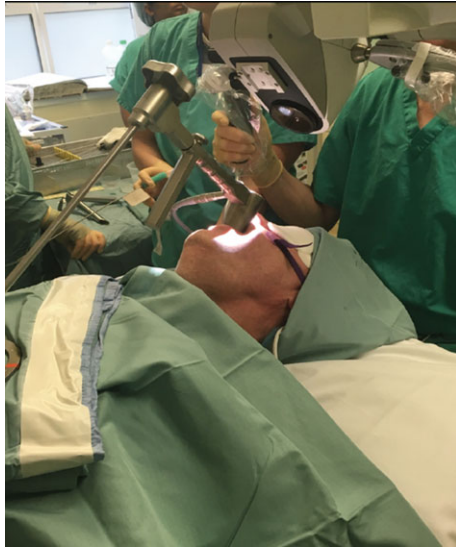


Figure 3 Apnoeic oxygenation provided via high-flow nasal cannulae (visible just under the eye mask worn by the patient) while a surgeon performs microlaryngeal surgery via a suspension laryngoscope.

tubeless anaesthesia for extended periods, in excess of that which is achievable with low-flow nasal oxygen and buccal oxygen administration (Fig. 3) [12, 27, 31, 71]. A summary of relevant case series is included in the Supporting Information (Table S1). Procedures have included vocal cord biopsy, injection thyroplasty and balloon dilatation of subglottic stenosis. One variation of the technique, undertaken by the authors of this article, involves pre-oxygenation with high-flow nasal oxygen followed by total intravenous anaesthesia with propofol and remifentanyl infusions and administration of a neuromuscular blocking drug [12]. Airway patency is maintained with jaw thrust or laryngoscopy while apnoeic oxygenation is undertaken with high-flow nasal oxygen ($F_{I}O_2$ 1.0) at flow rates of $80 \text{ l}\cdot\text{min}^{-1}$. Intra-operative monitoring includes venous blood gas analysis at 15-min intervals. Techniques to manage oxygen desaturation include: jet ventilation; temporary tracheal intubation using a microlaryngoscopy tube via the suspension laryngoscope or removal of the suspension laryngoscope; followed by conventional airway management, such as bag-mask ventilation or supraglottic airway device insertion.

Randomised controlled trials comparing the risks and benefits of tubeless anaesthesia with high-flow nasal oxygen vs. more traditional airway management have not yet been undertaken. Optimal $F_{I}O_2$ and flow rate settings for this technique are also unknown. Compression and absorption atelectasis leading to ventilation-perfusion mismatch are hypothesised as reasons for the limited duration of

successful oxygenation in the unobstructed apnoeic patient [10]. There is an ongoing trial (NCT03458091) aiming to quantify changes in lung volume by electrical impedance tomography during use of high-flow nasal oxygen for tubeless anaesthesia.

The absence of a tracheal tube precludes intra-operative end-tidal carbon dioxide measurement. Some clinicians undertake arterial or venous blood gas analysis during the apnoeic period [12, 27], whereas others await ET_{CO_2} measurement on completion of surgery [31, 71]. Clinicians must exert caution in interpreting ET_{CO_2} measurements as they underestimate the rate of carbon dioxide accumulation, and consequently, underestimate the degree of acidaemia [12, 27]. Transcutaneous PCO_2 measurement has also been used [12, 27].

Apnoeic oxygenation can be undertaken for rigid bronchoscopy with passive oxygen insufflation through the side port of the bronchoscope or a tracheal catheter [72, 73]. When low-flow insufflation is used, leak around the rigid bronchoscope can be prevented by packing the oropharynx with gauze [72]. Alternatively, high-flow nasal oxygen can exploit an incomplete seal around the bronchoscope in order to deliver oxygen to the lungs in an apnoeic state. High-flow administration of oxygen via the side port of a bronchoscope risks barotrauma if the path for gas egress becomes obstructed even for a brief period and is not recommended. Cases of tracheostomy formation under apnoeic oxygenation have also been described [74, 75].

Apnoeic oxygenation for the avoidance of lung movement

Apnoeic oxygenation of the deflated lung during one-lung ventilation reduces the likelihood of hypoxaemia and the need for resumption of double-lung ventilation [76, 77]. This can be achieved via an endobronchial suction catheter or, during bronchial anastomosis formation, via a surgically-placed catheter distal to the anastomosis.

Oxygen insufflation via a tracheal tube or endobronchial catheter has been used instead of conventional mechanical ventilation to improve surgical access during internal mammary artery harvest for coronary artery bypass grafting [26, 78].

Apnoeic oxygenation can enhance the quality of medical imaging by abolishing respiratory motion artefact, such as during computed tomography (CT) pulmonary angiography [79]. Apnoeic oxygenation can also prolong breath-holding in awake patients in order to maintain a static thorax for improved dose homogeneity during intensity-modulated radiotherapy [80].

Diagnosis of brain death

In the diagnosis of brain death, the absence of respiratory effort despite hypercapnia is consistent with absent brainstem respiratory reflexes and brainstem death. The apnoea test involves temporary suspension of mechanical ventilation, leading to hypercarbia and acidaemia, and is typically terminated when a pre-determined $P_a\text{CO}_2$ is attained [81]. Hypoxaemia is prevented by oxygen delivered through the tracheal tube via a catheter, T-piece or self-inflating bag system. Failure to attain an adequate $P_a\text{CO}_2$ rise for successful testing can be due to enhanced carbon dioxide clearance from an excessively high flow of oxygen [82, 83].

Cardiac arrest

The potential utility of apnoeic oxygenation combined with continuous chest compressions during cardiopulmonary resuscitation is recognised in guidelines of the American Heart Association (AHA) and European Resuscitation Council but is not routinely recommended [84, 85]. The AHA highlights witnessed out-of-hospital cardiac arrest with a shockable rhythm as a circumstance where positive pressure ventilation can be delayed in order to deliver three cycles of continuous chest compressions [84].

The ability of passive decompression of the thorax to generate a negative intrathoracic pressure, aiding alveolar ventilation and venous return, is contested [86, 87]. Continuous oxygen insufflation in lieu of positive pressure ventilation via a modified tracheal tube demonstrated comparable outcomes in a small randomised controlled trial in humans [88]. A retrospective analysis demonstrated more neurologically favourable survival with passive oxygen delivery via an oral airway compared with bag-mask ventilation after witnessed out-of-hospital cardiac arrest with a shockable rhythm [89]. More recently, a case of apnoeic oxygenation with high-flow nasal oxygen during a brief intra-operative maternal cardiac arrest has been reported [90].

Extracorporeal carbon dioxide removal

Combined use of apnoeic oxygenation and extracorporeal carbon dioxide removal (ECCO₂R) has been achieved in patients with acute respiratory distress syndrome (ARDS) [91]. 'Resting the lung' using extracorporeal assistance for gas exchange reduces systemic and pulmonary inflammatory mediators in experimental acute respiratory distress syndrome when compared with a conventional lung-protective ventilation strategy [92], and has been proposed as a mechanism of limiting ventilator-induced lung injury [93, 94]. Continued improvements in ECCO₂R

technologies, chiefly in the form of smaller dual lumen catheters for veno-venous ECCO₂R and reduced requirements for anticoagulation, may lead to greater use of 'ultra-protective' lung ventilation in the management of ARDS [95]. The results of multiple clinical trials are awaited [96].

Complications of apnoeic oxygenation

Hypercarbia, acidosis and the potential for hypoxaemia are key considerations for the clinician during apnoeic oxygenation. During testing for brain stem death, in addition to the patient's respiratory acidosis, a mild metabolic acidosis of unknown cause also develops during apnoeic oxygenation [97]. The acidaemia increases cardiac output by stimulating a tachycardia and reducing systemic vascular resistance. Mean arterial pressure typically exhibits a modest increase or remains unchanged. Mean pulmonary arterial pressure increases due to hypercarbia [98]. Post-hypercapnic hypotension is brief, mild and occurs in a minority of cases. Cardiac rhythm typically remains unaffected in the absence of profound acidaemia. The propensity for arrhythmias is greatly increased at a pH < 7.0 and exponentially so at a pH < 6.8 [99].

The critically ill patient undergoing apnoea testing is particularly vulnerable to adverse events, which may lead to circulatory arrest [100]. Perhaps the greatest risk is the potential for clinicians to be overconfident on the reliability of this technique to maintain oxygenation. A minimum requirement for success is a degree of airway patency, and if this is not achievable even with jaw thrust or during difficult airway management, then the patient may desaturate more rapidly than expected.

Apnoeic oxygenation does not deliver a volatile agent to the lungs, so there must be a plan to ensure adequate anaesthesia during airway management to avoid accidental awareness [101]. Similarly, tubeless anaesthesia with apnoeic oxygenation requires total intravenous anaesthesia [12, 27].

Laser use combined with administration of supplemental oxygen via an open system, such as apnoeic oxygenation for tubeless microlaryngeal surgery, is regarded as a high-risk situation for an airway fire [102]. However, the likelihood of native tissues rather than a tracheal tube acting as a fuel source is contested [103, 104]. A case of airway fire has occurred with the use of diathermy for hard palate biopsy in a patient receiving high-flow nasal oxygen [105].

Barotrauma is a risk if there is no clear route for gas egress during apnoeic oxygenation. During testing for brain stem death, insufflation rates < 10 l.min⁻¹, use of a

small catheter, placement of the catheter tip proximal to the carina or the use of non-catheter methods are all suggested as minimising this risk [82, 83]. Recent guidelines urge caution with simultaneous use of high-flow nasal oxygen and facemask ventilation [58]. Cases of pneumocephalus [106], pneumo-orbitus [107], epistaxis, subcutaneous emphysema, pneumomediastinum, pneumothorax [108, 109], oesophageal rupture and gastric rupture [110, 111] have all been reported with use of nasal cannulae, largely in paediatrics.

In the presence of upper airway soiling from bleeding or regurgitation, pharyngeal contents can be dispersed with high-flow oxygen insufflation, and a case of aspiration of gastric contents has been reported [112]. However, gastric insufflation has not been observed using ultrasonographic and computed tomographic assessment of gastric volumes [67, 113, 114]. Apnoeic oxygenation can be advantageous when incorporated into RSI techniques in circumstances where positive pressure ventilation before intubation could confer particular harm, such as the patient with tracheo-oesophageal fistula or pyloric stenosis [115, 116].

Conclusions

Apnoeic oxygenation can be employed in diverse clinical settings. It holds promise in reducing the likelihood of hypoxaemia as a component of a thorough airway management plan. Enthusiasm for apnoeic oxygenation needs to be accompanied with healthy caution and a greater degree of scientific rigour in emerging areas of use, such as tubeless anaesthesia. Further assessment is needed regarding which sub-populations are most likely to derive benefit from apnoeic oxygenation, the effects of varying flow rates and F_{iO_2} , methods of attenuating carbon dioxide elevation and its potential for reducing the risk of lung injury alongside advancements in extracorporeal technologies.

Acknowledgements

No external funding or competing interests declared.

References

- Hook M. An account of an experiment made by Mr. Hook, of preserving animals alive by blowing through their lungs with bellows. *Philosophical Transactions of the Royal Society of London* 1666; **2**: 539–40.
- Meltzer SJ, Auer J. Continuous respiration without respiratory movements. *Journal of Experimental Medicine* 1909; **11**: 622–5.
- Comroe JH Jr, Dripps RD. Artificial respiration. *Journal of the American Medical Association* 1946; **130**: 381–3.
- Enghoff H, Holmdahl MH, Risholm L. Diffusion respiration in man. *Nature* 1951; **168**: 830.
- Sleath GW, Jenkins LC, Graves HB. Diffusion in anaesthesia. *Canadian Anaesthetists' Society Journal* 1963; **10**: 72–82.
- Bartlett RG Jr, Brubach HF, Specht H. Demonstration of ventilatory mass flow during ventilation and apnea in man. *Journal of Applied Physiology* 1959; **14**: 97–101.
- Draper WB, Whitehead RW, Spencer JN. Studies on diffusion respiration: alveolar gases and venous blood pH of dogs during diffusion respiration. *Anesthesiology* 1947; **8**: 524–33.
- Holmdahl MH. Pulmonary uptake of oxygen, acid-base metabolism, and circulation during prolonged apnoea. *Acta Chirurgica Scandinavica Supplementum* 1956; **212**: 1–128.
- Kolettas A, Grosomanidis V, Kolettas V, et al. Influence of apnoeic oxygenation in respiratory and circulatory system under general anaesthesia. *Journal of Thoracic Disease* 2014; **6**: S116–45.
- Hostman S, Engstrom J, Sellgren F, Hedenstierna G, Larsson A. Non-toxic alveolar oxygen concentration without hypoxemia during apnoeic oxygenation: an experimental study. *Acta Anaesthesiologica Scandinavica* 2011; **55**: 1078–84.
- Slutsky AS, Watson J, Leith DE, Brown R. Tracheal insufflation of O_2 (TRIO) at low flow rates sustains life for several hours. *Anesthesiology* 1985; **63**: 278–86.
- Lyons C, Callaghan M. Apnoeic oxygenation with high-flow nasal oxygen for laryngeal surgery: a case series. *Anaesthesia* 2017; **72**: 1379–87.
- West JB, Hugh-Jones P. Pulsatile gas flow in bronchi caused by the heart beat. *Journal of Applied Physiology* 1961; **16**: 697–702.
- Rudlof B, Faldum A, Brandt L. Ventilatory mass flow during apnea: investigations on quantification. *Anaesthetist* 2010; **59**: 401–9.
- Tusman G, Suarez-Sipmann F, Peces-Barba G, et al. Pulmonary blood flow generates cardiogenic oscillations. *Respiratory Physiology and Neurobiology* 2009; **167**: 247–54.
- Mackenzie CF, Skacel M, Barnas GM, Brampton WJ, Alana CA. Effects of cardiac oscillations and lung volume on acinar gas mixing during apnea. *Journal of Applied Physiology* 1990; **68**: 2013–18.
- Shapiro BA. The apnea- P_aCO_2 relationship: some clinical and medico-legal considerations. *Journal of Clinical Anesthesia* 1989; **1**: 323–7.
- Solsona JF, Diaz Y, Gracia MP, Gener J, Vazquez A. P_aCO_2 becomes greater than P_vCO_2 during apnoea testing for brain death diagnosis. *Anaesthesia* 2010; **65**: 314–15.
- Gentz BA, Shupak RC, Bhatt SB, Bay C. Carbon dioxide dynamics during apneic oxygenation: the effects of preceding hypocapnia. *Journal of Clinical Anesthesia* 1998; **10**: 189–94.
- Stock MC, Schisler JQ, McSweeney TD. The P_aCO_2 rate of rise in anesthetized patients with airway obstruction. *Journal of Clinical Anesthesia* 1989; **1**: 328–32.
- Vivien B, Amour J, Nicolas-Robin A, et al. An evaluation of capnography monitoring during the apnoea test in brain-dead patients. *European Journal of Anaesthesiology* 2007; **24**: 868–75.
- Goudreau JL, Wijdicks EF, Emery SF. Complications during apnea testing in the determination of brain death: predisposing factors. *Neurology* 2000; **55**: 1045–8.
- Slutsky AS, Menon AS. Catheter position and blood gases during constant-flow ventilation. *Journal of Applied Physiology* 1987; **62**: 513–19.
- Smith RB, Babinski M, Bunegin L, Gilbert J, Swartzman S, Dirting J. Continuous flow apneic ventilation. *Acta Anaesthesiologica Scandinavica* 1984; **28**: 631–9.
- Babinski MF, Sierra OG, Smith RB, Leano E, Chavez A, Castellanos A. Clinical application of continuous flow apneic ventilation. *Acta Anaesthesiologica Scandinavica* 1985; **29**: 750–2.
- Watson RJ, Szarko R, Mackenzie CF, Sequeira AJ, Barnas GM. Continuous endobronchial insufflation during internal

- mammary artery harvest. *Anesthesia and Analgesia* 1992; **75**: 219–25.
27. Gustafsson IM, Lodenius A, Tunelli J, Ullman J, Jonsson-Fagerlund M. Apnoeic oxygenation in adults under general anaesthesia using transnasal humidified rapid-insufflation ventilatory exchange (THRIVE) – a physiological study. *British Journal of Anaesthesia* 2017; **118**: 610–17.
 28. Tang Y, Turner MJ, Baker AB. Effects of alveolar dead-space, shunt and V/Q distribution on respiratory dead-space measurements. *British Journal of Anaesthesia* 2005; **95**: 538–48.
 29. Windpassinger M, Plattner O, Gemeiner J, et al. Pharyngeal oxygen insufflation during airtraq laryngoscopy slows arterial desaturation in infants and small children. *Anesthesia and Analgesia* 2016; **122**: 1153–7.
 30. Steiner JW, Sessler DI, Makarova N, et al. Use of deep laryngeal oxygen insufflation during laryngoscopy in children: a randomized clinical trial. *British Journal of Anaesthesia* 2016; **117**: 350–7.
 31. Patel A, Nouraei SA. Transnasal humidified rapid-insufflation ventilatory exchange (THRIVE): a physiological method of increasing apnoea time in patients with difficult airways. *Anaesthesia* 2015; **70**: 323–9.
 32. Ward JJ. High-flow oxygen administration by nasal cannula for adult and perinatal patients. *Respiratory Care* 2013; **58**: 98–122.
 33. Moller W, Feng S, Domanski U, et al. Nasal high flow reduces dead space. *Journal of Applied Physiology* 2017; **122**: 191–7.
 34. Chanques G, Riboulet F, Molinari N, et al. Comparison of three high flow oxygen therapy delivery devices: a clinical physiological cross-over study. *Minerva Anestesiologica* 2013; **79**: 1344–55.
 35. Riera J, Perez P, Cortes J, Roca O, Masclans JR, Rello J. Effect of high-flow nasal cannula and body position on end-expiratory lung volume: a cohort study using electrical impedance tomography. *Respiratory Care* 2013; **58**: 589–96.
 36. Parke RL, Bloch A, McGuinness SP. Effect of very-high-flow nasal therapy on airway pressure and end-expiratory lung impedance in healthy volunteers. *Respiratory Care* 2015; **60**: 1397–403.
 37. Hinz J, Hahn G, Neumann P, et al. End-expiratory lung impedance change enables bedside monitoring of end-expiratory lung volume change. *Intensive Care Medicine* 2003; **29**: 37–43.
 38. McGinley BM, Patil SP, Kirkness JP, Smith PL, Schwartz AR, Schneider H. A nasal cannula can be used to treat obstructive sleep apnea. *American Journal of Respiratory and Critical Care Medicine* 2007; **176**: 194–200.
 39. Groves N, Tobin A. High flow nasal oxygen generates positive airway pressure in adult volunteers. *Australian Critical Care* 2007; **20**: 126–31.
 40. Ritchie JE, Williams AB, Gerard C, Hockey H. Evaluation of a humidified nasal high-flow oxygen system, using oxygraphy, capnography and measurement of upper airway pressures. *Anaesthesia and Intensive Care* 2011; **39**: 1103–10.
 41. Dysart K, Miller TL, Wolfson MR, Shaffer TH. Research in high flow therapy: mechanisms of action. *Respiratory Medicine* 2009; **103**: 1400–5.
 42. Greenspan JS, Wolfson MR, Shaffer TH. Airway responsiveness to low inspired gas temperature in preterm neonates. *Journal of Pediatrics* 1991; **118**: 443–5.
 43. Williams R, Rankin N, Smith T, Galler D, Seakins P. Relationship between the humidity and temperature of inspired gas and the function of the airway mucosa. *Critical Care Medicine* 1996; **24**: 1920–9.
 44. Fontanari P, Burnet H, Zattara-Hartmann MC, Jammes Y. Changes in airway resistance induced by nasal inhalation of cold dry, dry, or moist air in normal individuals. *Journal of Applied Physiology* 1996; **81**: 1739–43.
 45. Hermez LA, Spence CJ, Payton MJ, Nouraei SAR, Patel A, Barnes TH. Aphysiological study to determine the mechanism of carbon dioxide clearance during apnoea when using transnasal humidified rapid insufflation ventilatory exchange (THRIVE). *Anaesthesia* 2019; **74**: 441–9.
 46. Levitan RM. NO DESAT! Nasal oxygen during efforts securing a tube. *Emergency Physicians Monthly* 2010. <https://www.emmonthly.com/article/no-desat/> (accessed 13/05/2018).
 47. Frerk C, Mitchell VS, McNarry AF, et al. Difficult Airway Society 2015 guidelines for management of unanticipated difficult intubation in adults. *British Journal of Anaesthesia* 2015; **115**: 827–48.
 48. Marshall SD, Pandit JJ. Radical evolution: the 2015 Difficult Airway Society guidelines for managing unanticipated difficult or failed tracheal intubation. *Anaesthesia* 2016; **71**: 131–7.
 49. Apfelbaum JL, Hagberg CA, Caplan RA, et al. Practice guidelines for management of the difficult airway: an updated report by the American Society of Anesthesiologists Task Force on Management of the Difficult Airway. *Anesthesiology* 2013; **118**: 251–70.
 50. Myatra SN, Shah A, Kundra P, et al. All India Difficult Airway Association 2016 guidelines for the management of unanticipated difficult tracheal intubation in adults. *Indian Journal of Anaesthesia* 2016; **60**: 885–98.
 51. Wong DT, Yee AJ, Leong SM, Chung F. The effectiveness of apneic oxygenation during tracheal intubation in various clinical settings: a narrative review. *Canadian Journal of Anesthesia* 2017; **64**: 416–27.
 52. Mir F, Patel A, Iqbal R, Cecconi M, Nouraei SA. A randomised controlled trial comparing transnasal humidified rapid insufflation ventilatory exchange (THRIVE) pre-oxygenation with facemask pre-oxygenation in patients undergoing rapid sequence induction of anaesthesia. *Anaesthesia* 2017; **72**: 439–43.
 53. Lodenius A, Piehl J, Ostlund A, Ullman J, Jonsson-Fagerlund M. Transnasal humidified rapid-insufflation ventilatory exchange (THRIVE) vs. facemask breathing pre-oxygenation for rapid sequence induction in adults: a prospective randomised non-blinded clinical trial. *Anaesthesia* 2018; **73**: 564–71.
 54. Pavlov I, Medrano S, Weingart S. Apneic oxygenation reduces the incidence of hypoxemia during emergency intubation: a systematic review and meta-analysis. *American Journal of Emergency Medicine* 2017; **35**: 1184–9.
 55. Vourc'h M, Asfar P, Volteau C, et al. High-flow nasal cannula oxygen during endotracheal intubation in hypoxemic patients: a randomized controlled clinical trial. *Intensive Care Medicine* 2015; **41**: 1538–48.
 56. Jaber S, Monnin M, Girard M, et al. Apnoeic oxygenation via high-flow nasal cannula oxygen combined with non-invasive ventilation preoxygenation for intubation in hypoxaemic patients in the intensive care unit: the single-centre, blinded, randomised controlled OPTINIV trial. *Intensive Care Medicine* 2016; **42**: 1877–87.
 57. Frat JP, Ricard JD, Coudroy R, Robert R, Ragot S, Thille AW. Preoxygenation with non-invasive ventilation versus high-flow nasal cannula oxygen therapy for intubation of patients with acute hypoxaemic respiratory failure in ICU: the prospective randomised controlled FLORALI-2 study protocol. *British Medical Journal Open* 2017; **7**: e018611.
 58. Higgs A, McGrath BA, Goddard C, et al. Guidelines for the management of tracheal intubation in critically ill adults. *British Journal of Anaesthesia* 2018; **120**: 323–52.
 59. Pandit JJ, Irwin MG. Airway management in critical illness: practice implications of new Difficult Airway Society guidelines. *Anaesthesia* 2018; **73**: 544–8.

60. Jense HG, Dubin SA, Silverstein PI, O'Leary-Escolas U. Effect of obesity on safe duration of apnea in anesthetized humans. *Anesthesia and Analgesia* 1991; **72**: 89–93.
61. Baraka AS, Taha SK, Siddik-Sayyid SM, et al. Supplementation of pre-oxygenation in morbidly obese patients using nasopharyngeal oxygen insufflation. *Anaesthesia* 2007; **62**: 769–73.
62. Ramachandran SK, Cosnowski A, Shanks A, Turner CR. Apneic oxygenation during prolonged laryngoscopy in obese patients: a randomized, controlled trial of nasal oxygen administration. *Journal of Clinical Anesthesia* 2010; **22**: 164–8.
63. Mushambi MC, Kinsella SM, Popat M, et al. Obstetric Anaesthetists' Association and Difficult Airway Society tracheal intubation in obstetrics. *Anaesthesia* 2015; **70**: 1286–306.
64. Ramkumar V, Dinesh E, Shetty SR, et al. All India Difficult Airway Association 2016 guidelines for the management of unanticipated difficult tracheal intubation in obstetrics. *Indian Journal of Anaesthesia* 2016; **60**: 899–905.
65. Pillai A, Chikhani M, Hardman JG. Apnoeic oxygenation in pregnancy: a modelling investigation. *Anaesthesia* 2016; **71**: 1077–80.
66. Jones A. Apnoeic oxygenation in pregnancy. *Anaesthesia* 2016; **71**: 1491.
67. Riva T, Pedersen TH, Seiler S, et al. Transnasal humidified rapid insufflation ventilatory exchange for oxygenation of children during apnoea: a prospective randomised controlled trial. *British Journal of Anaesthesia* 2018; **120**: 592–9.
68. Humphreys S, Lee-Archer P, Reyne G, Long D, Williams T, Schibler A. Transnasal humidified rapid-insufflation ventilatory exchange (THRIVE) in children: a randomized controlled trial. *British Journal of Anaesthesia* 2017; **118**: 232–8.
69. Lyons C. Response to: transnasal humidified rapid insufflation ventilatory exchange for oxygenation of children during apnoea: a prospective randomised controlled trial. *British Journal of Anaesthesia* 2018; **121**: 512–13.
70. Woodman D. Laryngoscopy under general anesthesia: apnoeic oxygenation technique. A report of over 100 cases. *Annals of Otolaryngology and Laryngology* 1961; **70**: 1113–16.
71. To K, Harding F, Scott M, et al. The use of transnasal humidified rapid-insufflation ventilatory exchange in 17 cases of subglottic stenosis. *Clinical Otolaryngology* 2017; **42**: 1407–10.
72. Pathak V, Welsby I, Mahmood K, Wahidi M, MacIntyre N, Shofer S. Ventilation and anesthetic approaches for rigid bronchoscopy. *Annals of the American Thoracic Society* 2014; **11**: 628–34.
73. Cheattle CA, Chambers KB. Anaesthesia for bronchoscopy. *Anaesthesia* 1955; **10**: 171–2.
74. Go T, Altmayer M, Richter M, Macchiarini P. Decompressing manubriectomy under apneic oxygenation to release the median thoracic outlet compartment in Bechterew disease. *The Journal of Thoracic and Cardiovascular Surgery* 2003; **126**: 867–9.
75. Abeyundara L, Parker H, Fowler A, Patel A. The use of transnasal humidified rapid-insufflation ventilatory exchange (THRIVE) to facilitate tracheostomy under sedation. *Anaesthesia Cases* 2018. <https://www.anaesthesiacases.org/case-reports/2016-0009> (accessed 24/12/2018).
76. Jung DM, Ahn HJ, Jung SH, et al. Apneic oxygen insufflation decreases the incidence of hypoxemia during one-lung ventilation in open and thoracoscopic pulmonary lobectomy: a randomized controlled trial. *Journal of Thoracic and Cardiovascular Surgery* 2017; **154**: 360–6.
77. Sanchez-Lorente D, Gomez-Caro A, Jimenez MJ, Molins L. Apnoeic oxygenation on one-lung ventilation in functionally impaired patients during sleeve lobectomy. *European Journal of Cardiothoracic Surgery* 2011; **39**: e77–9.
78. Machan L, Churilov L, Hu R, et al. Apneic oxygenation versus low-tidal-volume ventilation in anesthetized cardiac surgical patients: a prospective, single-center, randomized controlled trial. *Journal of Cardiothoracic and Vascular Anesthesia* 2017; **31**: 2000–9.
79. Dragoumanis C, Papaianou V, Foutitzi S, Prassopoulos P, Pneumatikos I. Apneic oxygenation for elimination of respiratory motion artefact in an intubated patient undergoing helical computed tomography pulmonary angiography. *Journal of Radiology Case Reports* 2008; **2**: 5–7.
80. Roth J, Engenhardt-Cabillic R, Eberhardt L, Timmesfeld N, Strassmann G. Preoxygenated hyperventilated hypocapnic apnea-induced radiation (PHAIR) in breast cancer patients. *Radiotherapy and Oncology* 2011; **100**: 231–5.
81. Lang CJ, Heckmann JG. Apnea testing for the diagnosis of brain death. *Acta Neurologica Scandinavica* 2005; **112**: 358–69.
82. Australian and New Zealand Intensive Care Society. The ANZICS Statement on Death and Organ Donation, Edition 3.2. 2013. [https://csds.qld.edu.au/sdc/Provectus/ELI/Module%2020-%20Organ%20donation%20after%20brain%20death/files/ANZICS%20Statement%20on%20%20Death%20and%20Organ%20Donation%20Edition%203.2%20\(3\).pdf](https://csds.qld.edu.au/sdc/Provectus/ELI/Module%2020-%20Organ%20donation%20after%20brain%20death/files/ANZICS%20Statement%20on%20%20Death%20and%20Organ%20Donation%20Edition%203.2%20(3).pdf) (accessed 24/12/2018).
83. Wijdicks EF, Rabinstein AA, Manno EM, Atkinson JD. Pronouncing brain death: contemporary practice and safety of the apnea test. *Neurology* 2008; **71**: 1240–4.
84. Kleinman ME, Brennan EE, Goldberger ZD, et al. Part 5: adult basic life support and cardiopulmonary resuscitation quality: 2015 American Heart Association Guidelines Update for Cardiopulmonary Resuscitation and Emergency Cardiovascular Care. *Circulation* 2015; **132**: S414–35.
85. Soar J, Nolan JP, Bottiger BW, et al. European Resuscitation Council guidelines for resuscitation 2015: section 3. Adult Advanced Life Support. *Resuscitation* 2015; **95**: 100–47.
86. Moore JC, Lamhaut L, Hutin A, et al. Evaluation of the Boussignac cardiac arrest device (B-card) during cardiopulmonary resuscitation in an animal model. *Resuscitation* 2017; **119**: 81–8.
87. Peschanski N, Gillis M, Oudet J, Depil-Duval A, Chouihed T. Don't kill passive oxygenation with continuous oxygen insufflation too fast in cardiac arrest ventilation. *Resuscitation* 2017; **121**: e3–4.
88. Saissy JM, Boussignac G, Cheptel E, et al. Efficacy of continuous insufflation of oxygen combined with active cardiac compression-decompression during out-of-hospital cardiorespiratory arrest. *Anesthesiology* 2000; **92**: 1523–30.
89. Bobrow BJ, Ewy GA, Clark L, et al. Passive oxygen insufflation is superior to bag-valve-mask ventilation for witnessed ventricular fibrillation out-of-hospital cardiac arrest. *Annals of Emergency Medicine* 2009; **54**: e1.
90. Phillips S, Subair S, Husain T, Sultan P. Apnoeic oxygenation during maternal cardiac arrest in a parturient with extreme obesity. *International Journal of Obstetric Anesthesia* 2017; **29**: 88–90.
91. Gattinoni L, Agostoni A, Pesenti A, et al. Treatment of acute respiratory failure with low-frequency positive-pressure ventilation and extracorporeal removal of CO₂. *Lancet* 1980; **2**: 292–4.
92. Grasso S, Stripoli T, Mazzone P, et al. Low respiratory rate plus minimally invasive extracorporeal CO₂ removal decreases systemic and pulmonary inflammatory mediators in experimental Acute Respiratory Distress Syndrome. *Critical Care Medicine* 2014; **42**: e451–60.
93. Nielsen ND, Kjaergaard B, Koefoed-Nielsen J, Steensen CO, Larsson A. Apneic oxygenation combined with extracorporeal arteriovenous carbon dioxide removal provides sufficient gas exchange in experimental lung injury. *American Society for Artificial Internal Organs Journal* 2008; **54**: 401–5.

94. Gattinoni L, Carlesso E, Langer T. Clinical review: extracorporeal membrane oxygenation. *Critical Care* 2011; **15**: 243.
95. Combes A, Brechot N, Luyt CE, Schmidt M. Extracorporeal membrane oxygenation: beyond rescue therapy for acute respiratory distress syndrome? *Current Opinion in Critical Care* 2017; **23**: 60–5.
96. Fan E, Del Sorbo L, Goligher EC, et al. An Official American Thoracic Society/European Society of Intensive Care Medicine/Society of Critical Care Medicine Clinical Practice Guideline: mechanical ventilation in adult patients with acute respiratory distress syndrome. *American Journal of Respiratory and Critical Care Medicine* 2017; **195**: 1253–63.
97. Frumin MJ, Epstein RM, Cohen G. Apneic oxygenation in man. *Anesthesiology* 1959; **20**: 789–98.
98. Curley G, Laffey JG, Kavanagh BP. Bench-to bedside review: carbon dioxide. *Critical Care* 2010; **14**: 220.
99. Price HL. Effects of carbon dioxide on the cardiovascular system. *Anesthesiology* 1960; **21**: 652–63.
100. Scott JB, Gentile MA, Bennett SN, Couture M, MacIntyre NR. Apnea testing during brain death assessment: a review of clinical practice and published literature. *Respiratory Care* 2013; **58**: 532–8.
101. Pandit JJ, Andrade J, Bogod DG, et al. The 5th National Audit Project (NAP5) on accidental awareness during general anaesthesia: summary of main findings and risk factors. *Anaesthesia* 2014; **69**: 1089–101.
102. Apfelbaum JL, Caplan RA, Barker SJ, et al. Practice advisory for the prevention and management of operating room fires: an updated report by the American Society of Anesthesiologists Task Force on Operating Room Fires. *Anesthesiology* 2013; **118**: 271–90.
103. Ward P. THRIVE and airway fires. *Anaesthesia* 2017; **72**: 1035.
104. Roy S, Smith LP. Surgical fires in laser laryngeal surgery: are we safe enough? *Otolaryngology – Head and Neck Surgery* 2015; **152**: 67–72.
105. Onwochei D, El-Boghdady K, Oakley R, Ahmad I. Intra-oral ignition of monopolar diathermy during transnasal humidified rapid-insufflation ventilatory exchange (THRIVE). *Anaesthesia* 2017; **72**: 781–3.
106. Iglesias-Deus A, Perez-Munuzuri A, Lopez-Suarez O, Crespo P, Couce ML. Tension pneumocephalus induced by high-flow nasal cannula ventilation in a neonate. *Archives of Disease in Childhood. Fetal and Neonatal Edition* 2017; **102**: F173–5.
107. O'Brien BJ, Rosenfeld JV, Elder JE. Tension pneumo-orbitus and pneumocephalus induced by a nasal oxygen cannula: report on two paediatric cases. *Journal of Paediatrics and Child Health* 2000; **36**: 511–14.
108. Hegde S, Prodhan P. Serious air leak syndrome complicating high-flow nasal cannula therapy: a report of 3 cases. *Pediatrics* 2013; **131**: e939–44.
109. Baudin F, Gagnon S, Crulli B, Proulx F, Jouviet P, Emeriaud G. Modalities and complications associated with the use of high-flow nasal cannula: experience in a pediatric ICU. *Respiratory Care* 2016; **61**: 1305–10.
110. Alifano M, Veyrie N, Rabbat A. Pneumothorax, pneumomediastinum and hemorrhagic shock complicating oxygen administration through a nasopharyngeal catheter. *Annals of Thoracic Surgery* 2010; **90**: 2061.
111. Yao HH, Tuck MV, McNally C, Smith M, Usatoff V. Gastric rupture following nasopharyngeal catheter oxygen delivery—a report of two cases. *Anaesthesia and Intensive Care* 2015; **43**: 244–8.
112. Thomas P, Patel A, Nouraei R. Management of regurgitation during transnasal humidified rapid insufflation ventilatory exchange (THRIVE); a case report. Difficult Airway Society Annual Scientific Meeting 2017; Abstract 083. https://drive.google.com/file/d/1f17K4oO69TWEo_IIErUKdQ0Zb-fP9tOP/view (accessed 24/12/2018).
113. Sud A, Jefferson H, Athanassoglou V, Scott S. Comparison of CT-assessed gastric gas volume between patients receiving conventional pre-oxygenation and bag-mask ventilation versus THRIVE. Difficult Airway Society Annual Scientific Meeting 2017; Abstract 005. https://drive.google.com/file/d/1f17K4oO69TWEo_IIErUKdQ0Zb-fP9tOP/view (accessed 24/12/2018).
114. Hengen M, Bischoff G, Koessler S, et al. Evaluation of gastric insufflation during apneic oxygenation. Annual Meeting of the American Society of Anesthesiologists 2017; A2272. <http://www.asaabstracts.com/strands/asaabstracts/abstract.htm?year=2017&index=15&absnum=5083> (accessed 24/12/2018).
115. Kulkarni K, Karnik P, Dave N, Garasia M. Ultra-modified rapid sequence induction. *Pediatric Anesthesia* 2017; **27**: 1278.
116. Bhagwan SD. Levitan's no desat with nasal cannula for infants with pyloric stenosis requiring intubation. *Pediatric Anesthesia* 2013; **23**: 297–8.

Supporting Information

Additional supporting information may be found online in the Supporting Information section at the end of the article.

Table S1. Case series of tubeless anaesthesia using apnoeic oxygenation with high-flow nasal cannulae in adult populations.